

## Original Article

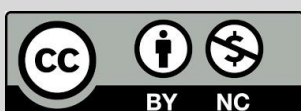# A Comparative Investigation Applying Testicular Fine Needle Aspiration Cytology and Open Testicular Biopsy Histology for the Diagnosis of Azoospermia and Severe Oligospermia

Othman, G. Q<sup>1,2,3\*</sup>, Mustafa, T. A<sup>1</sup>, Ismael, H. D<sup>1</sup>, Ali, S. S<sup>1</sup>, Abdullah, H. H<sup>1</sup>, Abdullah, B. U<sup>4</sup>

1. Department of Medical Laboratory Technology, Erbil Health and Medical Technical College, Erbil Polytechnic University, Erbil, Iraq
2. Department of Nursing, Shaqlawa Technical College, Erbil Polytechnic University, Erbil, Iraq
3. Department of Medical Laboratory Technology, Al-Qalam university college, Kirkuk, Iraq
4. Department of Biology, College of Education, Shaqlawa, Salahaddin University, Erbil, Kurdistan Region, Iraq

**How to cite this article:** Othman GQ, Mustafa TA, Ismael HD, Ali SS, Abdullah HH, Abdullah BU. A Comparative Investigation Applying Testicular Fine Needle Aspiration Cytology and Open Testicular Biopsy Histology for the Diagnosis of Azoospermia and Severe Oligospermia. *Archives of Razi Institute*. 2023;78(4):1343-8.

DOI: 10.32592/ARI.2023.78.4.1343



Copyright © 2023 by



Razi Vaccine & Serum Research Institute

## ABSTRACT

Open testicular biopsy histology and fine needle aspiration cytology (FNAC) are the most popular tests used to diagnose male infertility. This study aimed to assess the cytological characteristics of 186 infertile males aged 24-63 with testicular FNAC. Furthermore, the existing relationship between males with severe oligospermia (sperm count: 5 million/ml) and azoospermia was investigated via both cytological and histological diagnosis methods. With a 1.5-inch and 25-gauge needle, the testis was aspirated from three locations (the upper, middle, and lower poles). Papanicolaou stain or Giemsa stain was used to make smears on albumenized slides, which were then dried in the air and stained. A biopsy of the testicles was performed there, preserved in Bouins solution, processed as usual, and stained with hematoxylin and eosin stain. According to our findings, 66.7% of patients had secondary maturation arrest, whereas 18.3% and 15.1% of them had hypospermatogenesis and Sertoli cell only (SCO). Results of the comparison showed that both procedures were very similar. According to biopsy histological examinations, only 3 (1.6%) of the 28 normal FNAC instances had hypospermatogenesis with lymphocyte infiltration. The majority of SCO patients were over 50 years old. These findings revealed that FNAC is more effective than testicular histology for the assessment of male infertility.

**Keywords:** Aspiration, Azoospermia, Biopsy, Cytology, Oligospermia

### Article Info:

Received: 7 December 2022

Accepted: 15 January 2023

Published: 31 August 2023

**Corresponding Author's E-Mail:**  
goran.othman@epu.edu.iq

## 1. Introduction

Azoospermia can be defined as the lack of spermatozoa in the ejaculating semen. It is considered the severest type of male infertility. It constitutes roughly 1% of all men and accounts for about 5% of all infertile couples (1). A condition known as severe oligospermia occurs when the sperm count is less than  $5 \times 10^6/\text{mL}$  (Association and Medicine, 2004). Azoospermia is divided into obstructive and non-obstructive types. According to Kremer and Visser (2), obstructive azoospermia is defined as an obstruction or lack of the reproductive tract which prevents sperm cells from entering the seminal fluid before the process of ejaculation. The disruption of the spermatogenesis process, which includes hypo-spermatogenesis, arresting of sperm maturation, and total lack of spermatogonial cells (Sertoli cell-only [SCO]), is known as non-obstructive azoospermia (3).

The gonads examination, sperm tests, hormones evaluations, and sperm morphology examination of testicular biopsy are all part of the male infertility assessment. Male infertility was previously examined using testicular biopsy tissue, which is crucial for men whose fertility has been affected by obstructive azoospermia. Open biopsy is an essential operation for the categorization of the pathophysiology of infertility and the evaluation of the prognostic features. However, this approach is harsh and stressful and needs anesthesia, making it impossible to employ as a regular procedure (4).

Due to several factors, such as poor cooperation and concern on the part of the person performing the treatment, the fine needle aspiration cytology (FNAC) of the testis is rarely performed in ordinary practice. Interest of numerous pathologists in FNAC has led to the standardization of the process, which has improved the correlation between testis cytology and histology (5).

The present investigation was performed to find out whether fine needle aspiration could be used as an alternative method for conventional biopsy for diagnostic purposes to avoid invasive and expensive

intervention. Another purpose of this research was to determine whether the FNAC of azoospermia testes could replace the biopsy of those testes.

## 2. Materials and Methods

### 2.1. Patient Evaluation and Sampling

This prospective study will be completed over two years. In total, this study was performed on 186 patients with primary infertility in teaching hospitals in Hawler City, Kurdistan area, Iraq. To identify varicocele, 186 patients were all subjected to a Doppler examination. In an aseptic atmosphere, the patients had FNAC and a biopsy simultaneously. The participants had an average age of 41.84 years old, ranging from 24 to 63 years old, with the range of 50-60 years old being the most common age range. After collection of the medical history of participants and the performance of a clinical evaluation, the semen was analyzed in triplicate or duplicate with a three-week time interval between the samplings.

The aspiration process was explained to the patients, and with their consent, they were then put in a horizontal position while their scrotums were cleaned with a 70% alcohol swab and sterilely draped as is customary. Securing the vas deferens slightly below the scrotal skin with the three-finger technique, 2 ml of 1% Lidocaine was injected into the spermatic cord. The vas deferens was injected with lignocaine using a 25 gauge 1.5-inch needle. Both testes were sampled for FNA in order to assess spermatogenesis. The exact locations were used for a testicular biopsy. Slides made from aspiration material were either air-dried and stained with Giemsa stain or treated with alcohol and stained with Papanicolaou stain (6).

### 2.2. Sample Analysis

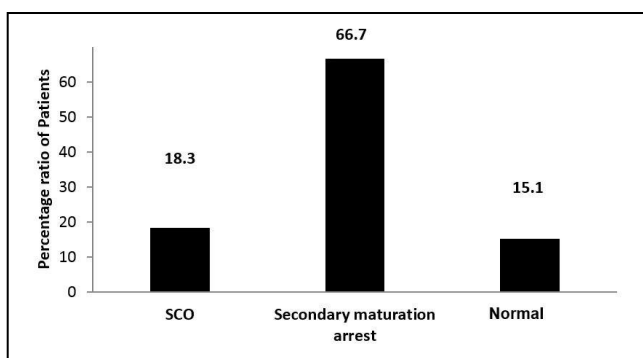
When at least 1,000 cells were recovered, the aspirate was considered adequate. According to morphologic criteria, the cells were divided into three groups, namely normal spermatogenesis, SCO syndrome, and secondary maturation (2). Testicular biopsy samples were cut into sections and processed using the traditional paraffin method, then stained with

hematoxylin and eosin. The study samples were categorized into three categories during the reading of the slides, namely normal and active spermatogenesis, hypo-spermatogenesis with lymphocyte infiltration, and SCO (7).

### 3. Results

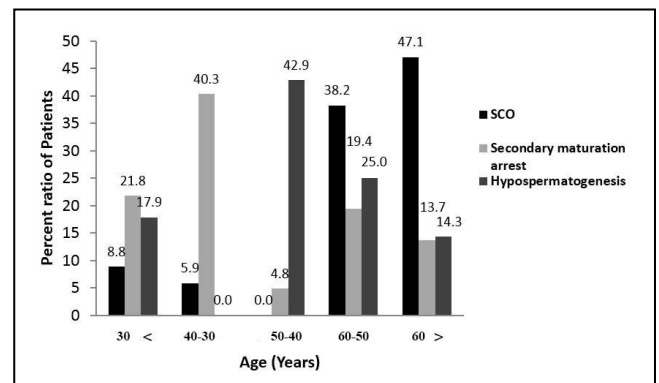
In total, 186 infertile patients had their testicles sampled using FNAC. Following cell counts, the percentages of various cell types were noted. The infertility of male patients was diagnosed using this cell-type characterization. According to FNAC procedure records, the results of the present study demonstrated that almost two-thirds (66.7%) of the investigated patients displayed sperm-growing arrest during the phase of secondary spermatocytes (Figure 1). Moreover, SCO, in which no germ cells were detected, impacted 18.3% of the population. In addition, 15.1% of the patients had mature sperm in significant numbers and normal spermatogenesis, while the number of spermatids was lower but still within the normal range.

The samples in the present study ranged in age from 24 to 63 years old with a mean age of 41.84 years old. Patients within the age range of 50-60 years old made up most of the sample population.



**Figure 1.** Spermatogenesis cell types distributions are observed in testicular fine needle aspiration (FNA) cytology smears and used to diagnose 186 infertile male patients. The information is displayed as percentage values (%). Sertoli cells only are referred to as SCO

According to the spermatogenesis categorization and cell type classification, which was used to determine infertility in patients according to age groups, as shown in figure 2, the majority of infertile men with SCO were elderly individuals older than 50 years, while the scores for the age groups of below 30 and 30-40 years old were 8.8% and 5.9% respectively.



**Figure 2.** Distribution of spermatogenesis according to the patient's age. All data are referred to as per cent values (%). SCO stands for Sertoli cells only

The FNAC was reported in 186 patients and biopsy procedures were performed simultaneously in an aseptic environment. The exact locations were used for a testicular biopsy. This study aimed to analyze and contrast the outcomes of these two approaches. The findings summarized in table 1 showed that both approaches had an excellent agreement. In total, 28 cases of normal FNA were examined, but only 3 cases (1.6%) revealed hypospermatogenesis with lymphocyte infiltration.

Results of the biopsy histology were almost exactly matched by the Secondary maturation arrest (SA) in FNAC. Only 5 out of 124 SA cases in FNA were found to have hypospermatogenesis with lymphocyte infiltration in the testicles. Additionally, SCO used both methodologies to reach the same conclusion.

**Table 1.** FNA and testicular biopsy methods comparison among infertile male patients

FNA	Biopsy			SCO	Total
	Normal and active sperm.	Hyosper. with lymphocytes infiltration	Negative for active sperm.		
Normal	25 (13.4%)	3 (1.6%)	0	0	28(15.1%)
*SA	0	5 (2.7%)	119 (64.0%)	0	124(66.7%)
**SCO	0	0	0	34 (18.3%)	34(18.3%)

#### 4. Discussion

The current investigation was the first study conducted in Hawler City, Kurdistan Region, Iraq, in which 186 infertile male patients underwent both a testicular FNAC and a histology-examined biopsy. In this study, the majority of patients (66.7%) had spermatocytes that had stopped maturing at the secondary stage. While SCO (18.3%), in which no germ cells were detected, were damaged, 15.1% of the patients displayed normal spermatogenesis with a sizable amount of mature sperm. Characterizing various spermatogenic cell types is crucial since, as confirmed by other researchers, it can diagnose azoospermia and oligospermia from cytological smears (8).

Posner and Huhner initially utilized testicular puncture biopsies to investigate unstained spermatozoa samples to study human infertility. Later, a non-invasive procedure called fine needle testicular aspiration was suggested by Mallidis and Baker (9). Identification of the different cell types in cytological smears was simple, and germ and Sertoli cells were easy to spot. The FNAC material is sufficient, and the different cell types can be distinguished by their characteristic appearance. The population of germ cells has been subjected to quantitative analysis by several researchers. On cytological smears, the ratio of Sertoli cells, other germ cells, and spermatozoa aid in making the diagnosis (10).

In a related study performed in 2003 by Kurien (11), 57 patients were examined. In the aforementioned study, except for three individuals who had secondary infertility, practically all of the patients had primary infertility. Varicoceles were found in 12 patients, 37

patients had azoospermia verified by 3 semen assays, and the remaining patients had oligospermia.

According to the most recent data, secondary maturation arrest predominantly affected patients between the ages of 30 and 40, with a percentage of 40.3%. Although, except for those aged 40-50 years old, similar distributions of secondary maturation arrest were discovered in other age groups. This immature spermatid in the ejaculate has caused a maturation arrest, which suggests difficulty in becoming pregnant.

This finding was in line with that of a study performed by Ali, Alnajjar (6), which revealed that nearly half of the evaluated infertile patients were within the age range of 30-39 years old. In the present study, FNAC and biopsy were performed on all 186 individuals in the exact location, using the same testicular sites. Moreover, this study analyzed and contrasted the outcomes of these two approaches. A good agreement was observed between the two methods. In total, 28 cases of normal FNA were examined, but only 3 cases (1.6%) revealed hyospermatogenesis with lymphocyte infiltration.

Results of the biopsy histology were almost exactly matched by the SA in FNAC. Only 5 out of 124 SA cases in FNA were found to have hyospermatogenesis with lymphocyte infiltration in the testicles. Additionally, SCO used both methodologies to reach the same conclusion. In order to investigate male infertility and obtain spermatozoa for intracytoplasmic sperm injection-assisted conception, it has previously been suggested to give FNA some consideration (12).

In a study conducted by Yadav, Rai (13), 25 infertility patients with the condition were examined. In the aforementioned study, most of the patients were within

the age range of 26-30 years old and sought help after living together for 4-6 years. In that study, 22 cases of primary infertility and 3 cases of secondary infertility were present. Among them, 4 individuals had oligospermia, 21 patients had azoospermia, and 4% had a left-sided varicocele. Moreover, 69% of males had testicles of standard size and the histological diagnostic results of normal spermatogenesis, while 62.5% of them had testicles that were too small and had the diagnosis of SCO syndrome or testicular atrophy.

Additionally, previous studies have demonstrated that systematic test collection using FNA rather than testicular biopsy yields more information about spermatogenesis (14). Cito, Becatti (15) performed a semen analysis and testicular biopsy on 42 azoospermic males and found that FNAC was the most frequent diagnosis, with maturation arrest (49%). In their study, histology, the gold standard for precise diagnosis, and FNAC had an 86% correlation ( $P=0.801$ ).

In conclusion, it could be stated that the testicular FNAC is a quick and less invasive treatment that can differentiate between the obstructive and the non-obstructive types of azoospermia in testicular histology. During male infertility assessment, testis FNAC could be applied instead of testis biopsy histology as they provide similar results.

#### Authors' Contribution

Study concept and design: G. Q. O.

Acquisition of data: T. A. M.

Analysis and interpretation of data: H. D. I.

Drafting of the manuscript: S. S. A.

Critical revision of the manuscript for important intellectual content: H. H. A.

Statistical analysis: B. U. A.

Administrative, technical, and material support: G. Q. O.

#### Ethics

The ethical approval was obtained from the ethics committee of the Erbil Polytechnic University, Erbil, Iraq.

#### Conflict of Interest

The authors declare that they have no conflict of interest.

#### References

- Oates R. Evaluation of the azoospermic male. *Asian J Androl.* 2012;14(1):82-7.
- Kremer JA, Visser H. Testicular sperm extraction (TESE) with intracytoplasmic sperm injection (ICSI) now allowed in the Netherlands. *Ned Tijdschr Geneesk.* 2008;152(3):164-6.
- Behre HM, Bergmann M, Simoni M, Tüttelmann F. Primary testicular failure. 2015.
- Charny CW. Testicular biopsy: Its value in male sterility. *J Am Med Assoc.* 1940;115(17):1429-33.
- Jha R, Sayami G. Testicular fine needle aspiration in evaluation of male infertility. *J Nepal Med Assoc.* 2009;48(173):78-84.
- Ali SA, Alnajjar SM, Hasan ZB. The role of FNA cytology of the testis in management of male infertility (In Iraq). *Zanco J Med Sci.* 2012;16(3):233-40.
- Purohit TM, Purohit MB, Dabhi BJ. Study of semen analysis and testicular biopsy in infertile male. *Indian J Pathol Microbiol.* 2004;47(4):486-90.
- Dohle GR, Elzanaty S, van Casteren NJ. Testicular biopsy: clinical practice and interpretation. *Asian J Androl.* 2012;14(1):88-93.
- Mallidis C, Baker HW. Fine needle tissue aspiration biopsy of the testis. *Fertil Steril.* 1994;61(2):367-75.
- Foresta C, Varotto A, Scandellari C. Assessment of testicular cytology by fine needle aspiration as a diagnostic parameter in the evaluation of the azoospermic subject. *Fertil Steril.* 1992;57(4):858-65.
- Kurien BT. The patience of patients. *Med J Aust.* 2003;179(11):653-.
- Craft I, Tsirigotis M, Courtauld E, Farrer-Brown G. Testicular needle aspiration as an alternative to biopsy for the assessment of spermatogenesis. *Hum Reprod.* 1997;12(7):1483-7.
- Yadav H, Rai U, Singh R. Radiofrequency radiation: A possible threat to male fertility. *Reprod Toxicol.* 2021;100:90-100.
- Meng MV, Cha I, Ljung BM, Turek PJ. Relationship between classic histological pattern and sperm findings on fine needle aspiration map in infertile men. *Hum Reprod.* 2000;15(9):1973-7.

15. Cito G, Becatti M, Natali A, Fucci R, Picone R, Cocci A, et al. Redox status assessment in infertile patients with non-obstructive azoospermia undergoing testicular sperm extraction: A prospective study. *Andrology*. 2020;8(2):364-71.